

# We are IntechOpen, the world's leading publisher of Open Access books Built by scientists, for scientists

5,900

Open access books available

145,000

International authors and editors

180M

Downloads

Our authors are among the

154

Countries delivered to

TOP 1%

most cited scientists

12.2%

Contributors from top 500 universities



WEB OF SCIENCE™

Selection of our books indexed in the Book Citation Index  
in Web of Science™ Core Collection (BKCI)

Interested in publishing with us?  
Contact [book.department@intechopen.com](mailto:book.department@intechopen.com)

Numbers displayed above are based on latest data collected.  
For more information visit [www.intechopen.com](http://www.intechopen.com)



---

# Raynaud's Phenomenon

---

Sevdalina Nikolova Lambova

Additional information is available at the end of the chapter

<http://dx.doi.org/10.5772/intechopen.79362>

---

## Abstract

Raynaud's phenomenon (RP) is a clinical consequence of recurrent vasospasm of the small arteries and arterioles of the fingers and toes provoked by cold and emotional stress. RP is classified into two categories, i.e., primary and secondary RP. Primary RP is an isolated finding in the absence of an underlying pathology, while secondary RP is a syndrome in the context of another disease. The patients with primary RP have a younger age at onset, sparing of the thumb, and benign course without development of digital ulcers. Contrarily, secondary RP is characterized with later age of onset above 30 years, thumb involvement, and more severe course with possible development of trophic changes. In these cases, a focused, complaint-directed history and physical examination aim to reveal clinical symptoms and findings that confirm the presence of an underlying disorder, e.g., connective tissue disease (CTD) or other pathology. Together with clinical examination, laboratory, immunological, and capillaroscopic assessments facilitate the internal differential diagnosis of secondary RP. The capillaroscopic examination should be performed in all patients with symptoms of RP even in those cases without signs of systemic rheumatic disease, because the abnormal capillaroscopic picture inherits a high positive predictive value for the development of CTD.

**Keywords:** Raynaud's phenomenon, primary, secondary, peripheral vascular syndromes, capillaroscopy

---

## 1. Definition

The term "Raynaud's phenomenon" (RP) originates from the name of the French physician Maurice Raynaud, who described transient digital ischemia provoked by cold exposure and hypothesized that the changes are associated with exaggerated response of the central nervous system. Currently, the term "RP" defines the clinical consequence of recurrent vasospasm of the small arteries, arterioles, and arteriovenous shunts of the fingers and toes provoked by

cold and emotional stress [1]. Other acral parts, e.g., the nose, lips, and ears, may be also affected. It manifests usually in three phases, ischemia, asphyxia, and reactive hyperemia, during which skin color changes occur consecutively from white to blue and red. A characteristic feature of RP is the clear demarcation between the affected and unaffected area.

## 2. Diagnosis of Raynaud's phenomenon

The diagnosis of RP is clinical and is based on direct observation of the vasospastic attacks [1]. Photographs that document the vasospastic attacks could also be used to confirm the history [2]. In routine clinical practice, it is not necessary to perform a cold provocation test to make a definite diagnosis of RP [1].

Observation of at least biphasic color changes is necessary for the diagnosis, as pallor and cyanosis are considered to be the most important signs. In a recent international consensus for the diagnosis of RP (Maverakis et al. [3]), a three-step approach for the diagnosis of RP has been suggested. The first two steps include asking more general questions: (I) a question about unusual sensitivity of the fingers to cold and (II) a question about "occurrence of biphasic color changes during the vasospastic episodes (white and blue)." Finally, during step III, the physician calculates the disease score by asking seven questions to the patient ((1) episodes are triggered by factors other than cold, i.e., emotional stress; (2) episodes involve both hands even if they are asynchronous or asymmetric; (3) numbness and paresthesias accompany vasospastic attacks; (4) well-demarcated border between the affected and unaffected skin; (5) photographs provided by the patient; (6) vasospastic episodes that affect other body parts such as the nose, ears, feet, and areolas; (7) occurrence of triphasic color changes during vasospastic attacks, e.g., white, blue, and red). If the score from step III is  $\geq 3$ , the patient is diagnosed with RP [3].

## 3. Classification of Raynaud's phenomenon

RP is classified into two categories, i.e., primary and RP [1, 4, 5, 6].

Primary RP is an isolated finding in the absence of an underlying pathology, while secondary RP is a syndrome in the context of another disease. The patients with primary RP have a younger age of onset (below 30 years), sparing of the thumb, and benign course without the development of digital ulcers [4, 6, 7].

On the contrary, secondary RP is characterized with later age of onset above 30 years, thumb involvement, and a more severe course with possible development of trophic changes in some cases (digital ulcerations, digital necrosis) [4, 6, 7]. In these cases, a focused, complaint directed history and physical examination aim to reveal clinical symptoms and findings that confirm the presence of an underlying disease, e.g., connective tissue disease (CTD) or other disorders. The secondary RP is a characteristic feature in a number of rheumatic diseases. In systemic

sclerosis (SSc)/scleroderma, it is with the highest frequency of approximately 95% [8]. RP could also be a sign in a spectrum of nonrheumatic pathology that also should be recognized and properly differentiated by the rheumatologists in routine clinical practice (**Table 1**) [8–14].

Together with clinical examination, laboratory, immunological, and capillaroscopic assessments facilitate the internal differential diagnosis of secondary RP and reveal the definite final diagnosis.

*Nailfold capillaroscopy* is a noninvasive, easy-to-perform method for diagnosis and differential diagnosis of patients with primary and secondary RP in rheumatic diseases (particularly the scleroderma-spectrum disorders), which is of crucial importance because of the different severity, prognosis, and therapeutic approach. Normal capillaroscopic pattern is an established diagnostic criterion for the diagnosis of primary RP. In addition, it has been found that capillaroscopic pattern in healthy individuals is constant for long periods of time. During the follow-up of patients with RP, it has been found that the appearance of abnormal capillaroscopic findings inherits a positive predictive value of 47% for the development of CTD that is higher as compared with the predictive value of the positive antinuclear autoantibody (ANA) test (30%) [15]. The appearance of giant capillaries is the earliest capillaroscopic sign of microangiopathy and represents a local response to tissue hypoxia. In RP patients, nailfold capillaroscopic analysis should be performed every 6 months and more often if new alarming symptoms appear. The capillaroscopic examination should be performed in all patients with symptoms of RP even in those cases without clinical and laboratory signs of systemic rheumatic disease, because the abnormal capillaroscopic picture inherits a high positive predictive value for the development of CTD.

---

Systemic sclerosis

Mixed connective tissue disease

Undifferentiated connective tissue disease

Systemic lupus erythematosus

Dermatomyositis, polymyositis

Sjögren syndrome

Rheumatoid arthritis

Systemic vasculitides-Buerger disease, Takayasu arteritis, polyarteritis nodosa, granulomatosis with polyangiitis, etc.

Fibromyalgia

Cryoglobulinemia

Drug-induced Raynaud's phenomenon—beta-blockers, cytotoxic drugs, vinblastine, bleomycin, interferon, etc.

Paraneoplastic Raynaud's phenomenon—associated with solid tumors and hematological malignancies

Endocrine disorders—hypothyroidism

Neurologic disorders—carpal tunnel syndrome

---

**Table 1.** Differential diagnosis of secondary Raynaud's phenomenon in rheumatologic practice.

## 4. Pathogenesis of Raynaud's phenomenon

The vasospasm in primary RP is reversible, while the secondary Raynaud's phenomenon in systemic sclerosis is associated with endothelial injury and subsequent structural abnormalities that lead to tissue damage.

*Adrenergic alpha-2 receptors* that are more important than alpha-1 receptors in the control of vasoconstriction of digital arteries are suggested to be abnormal in RP. The receptor subtype alpha-2c is found to predominate in the vascular smooth muscle cells of distal cutaneous vessels [16, 17]. Alpha-2c adrenergic receptors are not active at room temperature. In response to cold exposure, they are activated as a result from translocation from the Golgi complex to the plasmatic membrane [18, 19]. Estrogens also activate alpha-2c adrenoreceptors that could explain the predominance of primary RP in females and the increased severity of symptoms between menarche and menopause [20]. An association between enhanced contractile response to alpha-2c agonists and increased protein tyrosine kinase activity and tyrosine phosphorylation has been found. Greater intracellular tyrosine phosphorylation in response to cooling (31°C) has been found in arterioles in both primary and secondary RP patients vs. controls using immunofluorescence and an antiphosphotyrosine antibody [21, 22].

The endothelium controls blood vessel tone via production of vasodilators (nitric oxide (NO), prostacyclin) and vasoconstrictors (endothelin-1, angiotensin). Endothelial damage in secondary RP in SSc leads to disbalance between vasodilators and vasoconstrictors [10, 23]. In SSc-related RP, increased level of asymmetric dimethylarginine (an endogenous NO synthesis inhibitor produced by endothelial cells) was observed. Elevated plasma level of endothelin-1 was found in SSc as compared with primary RP [24]. Increased expression of endothelin-1 in the skin of SSc patients was also detected [25]. Besides its properties of vasoconstrictor, it has been confirmed that endothelin-1 promotes fibrosis in scleroderma patients [26]. In SSc, endothelial injury represents a key pathogenic step that mediates the processes of inflammation, thrombus formation, and fibrosis [23]. The role of endothelin-1 in pathogenesis of primary RP has also been implicated in some studies, but the evidence is weaker in comparison with SSc [10, 27].

Calcitonin gene-related peptide (CGRP) is a neuropeptide and a potent vasodilator produced by peripheral sensory nerves. In RP (primary and secondary RP in SSc), especially the secondary forms in SSc, a reduction in the number of CGRP immunoreactive neurons in the skin was found [28].

## 5. Primary Raynaud's phenomenon

In a recent systematic literature review, the prevalence of primary RP is reported to vary from 1.6 to 7.2% (calculated pooled prevalence—4.85%) [29]. As mentioned above, the primary RP is characterized with early age of onset, mainly at puberty. This classic type of presentation predominates in female patients with family history. Despite the fact that the age of onset is considered to be a discriminating factor between primary and secondary RP, it should be interpreted individually as primary RP with late onset (above the age of 40) is also possible [30].

### 5.1. Diagnosis of primary Raynaud's phenomenon

Wide application in clinical practice have the diagnostic criteria of Le Roy and Medsger (1992) that encompass the following findings:

1. Vasospastic attacks precipitated by cold or emotional stress
2. Symmetric attacks
3. Absence of digital ulcerations or gangrenes
4. Normal erythrocyte sedimentation rate
5. Negative test for ANA
6. Normal capillaroscopic picture [31]

Maverakis et al. published an international consensus for diagnosis of primary RP, which includes the following criteria: (1) normal capillaroscopy; (2) negative physical examination for findings suggestive of secondary causes such as ulcerations, tissue necrosis or gangrene, sclerodactyly, calcinosis, or skin fibrosis; (3) no history of existing CTD; and (4) negative or low titer ANA as low titer is considered (1:40) by indirect immunofluorescence. In the newly accepted criteria of Maverakis et al., the presence of normal erythrocyte sedimentation rate is not included, and negative test for ANA is not required [3] (**Table 2**). Normal capillaroscopic pattern exists in both sets of criteria.

In primary RP, capillary morphology and capillary density are normal. Slightly enlarged capillary diameters could be found [32–34].

## 6. Secondary Raynaud's phenomenon

Older age of onset, thumb involvement, severe course with trophic alterations of the fingers (digital ulcers, digital necrotic lesions), clinical features suggestive of autoimmune disease, positive autoantibodies, and abnormal capillaroscopic findings are characteristic features of secondary RP in rheumatic diseases [4, 6, 7].

### 6.1. Raynaud's phenomenon in systemic sclerosis

RP is one of the most common symptoms in SSc with frequency of about 95% [8]. It is usually the initial clinical feature that appears years before other disease symptoms. SSc-related RP is severe and often complicates with development of digital ulcers. The capillaroscopic pattern in SSc is specific and is characterized with the presence of dilated and giant capillaries, hemorrhages, avascular areas, and neoangiogenic capillaries. It has been described by Maricq et al. and is termed "scleroderma" type capillaroscopic pattern, which is a reference capillaroscopic pattern in rheumatology. Maricq et al. also observed components of this pattern in diseases from the scope of scleroderma-spectrum disorders, e.g., mixed connective tissue disease (MCTD), undifferentiated connective tissue disease (UCTD), and dermatomyositis (DM)—the so-called "scleroderma-like" pattern [35–37].

Le Roy and Medsger [31]	Maverakis et al. [3]
1. Vasospastic attacks precipitated by cold or emotional stress	1. Normal capillaroscopy
2. Symmetric attacks	2. Negative physical examination for findings suggestive of secondary causes (e.g., ulcerations, tissue necrosis or gangrene, sclerodactyly, calcinosis, or skin fibrosis)
3. Absence of digital ulcerations or gangrenes	3. No history of existing CTD
4. Normal erythrocyte sedimentation rate	4. Negative or low titer ANA (e.g., 1:40 by indirect immunofluorescence)
5. Negative test for ANA	
6. Normal capillaroscopic picture	

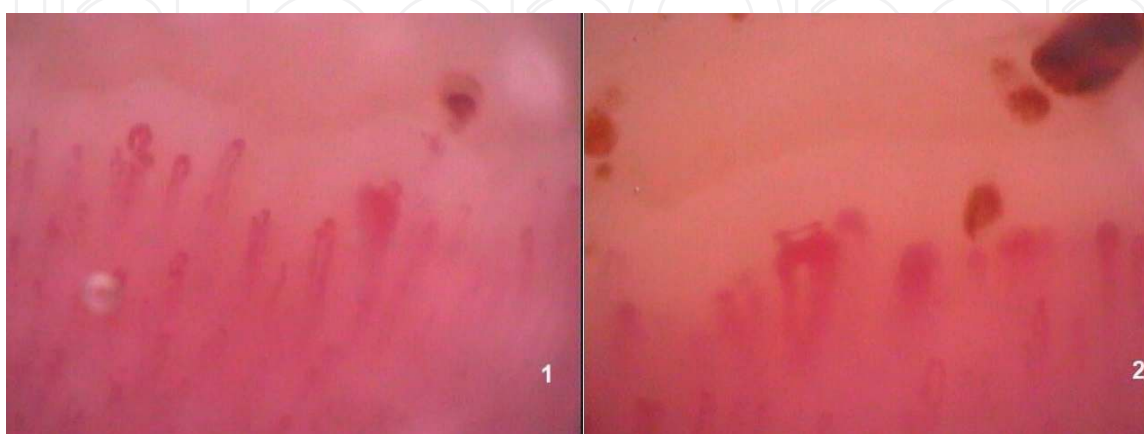
**Table 2.** Diagnostic criteria for primary Raynaud's phenomenon (Le Roy and Medsger [31]; Maverakis et al. [3]).

Cutolo et al. [38] described three phases of capillaroscopic changes in SSc:

- I. An "early" phase—appearance of few dilated and/or giant capillaries and few hemorrhages. In this phase, the distribution is relatively preserved without loss of capillaries.
- II. An "active" phase—the changes in this phase include a higher number of giant capillaries and hemorrhages, a moderate loss of capillaries, slight derangement, and, in some cases, diffuse pericapillary edema (**Figure 1**).
- III. A "late" phase—it is characterized with extensive avascular areas, severe capillary derangement, and bushy and ramified capillaries [38].

"Scleroderma" type capillaroscopic pattern is found in the majority of SSc patients (about 90%). Maricq et al. detected "scleroderma" pattern in 82–95% of SSc patients [36, 37]. In an own study, "scleroderma" pattern of the hands was detected in 97.2% (35/36) of SSc patients [34, 39, 40].

In addition, it has been found that a number of patients with a definite diagnosis of SSc (those with sclerodactyly, telangiectasia, subcutaneous calcinosis, esophageal dysmotility, etc.) do not fulfill the ACR (American College of Rheumatology) classification criteria for the disease (1980). An abnormal "scleroderma" type capillaroscopic pattern was found in these cases [41].



**Figure 1.** "Scleroderma type" capillaroscopic pattern in SSc (1) "early" phase, there is a single giant capillary loop and a single hemorrhage; (2) "active" phase, magnification 200×.

For establishing the diagnosis of SSc according to the ACR criteria (1980), the presence of the major criterion (skin thickening proximal to metacarpophalangeal joints of the hands) or two minor criteria ((1) sclerodactyly, (2) fingertip pitting scars, (3) bibasilar pulmonary fibrosis) is required [42]. These criteria have been proposed prior to the discovery of SSc-related autoantibodies and the characteristic capillaroscopic findings, which both had been found to improve the early diagnosis of SSc [43, 44]. Thus, Le Roy and Medsger suggested patients with RP and "scleroderma" type capillaroscopic changes or positive SSc-related autoantibodies to be diagnosed as "prescleroderma" or *limited SSc* even if other disease symptoms are absent [45]. The multicenter project VEDOSS (Very Early Diagnosis of Systemic Sclerosis) resulted in the new classification criteria for SSc (European League Against Rheumatism (EULAR)/ACR, 2013), which aim to detect SSc in early stages. In the new EULAR/ACR classification criteria, RP is scored with 3 points (1), the abnormal capillaroscopic pattern with 2 points (2), and presence of SSc-related autoantibodies (anticentromere, anti-topoisomerase I (anti-Scl-70), anti-RNA polymerase) with 3 points (maximum score for the immunologic criterion is 3) (3). The other criteria (overall 8 criteria) are as follows: telangiectasia (2 points) (4); fingertip lesions (digital tip ulcers - 2 points or fingertip pitting scars - 3 points), only the higher score is counted (5); pulmonary arterial hypertension and/or interstitial lung disease are scored with 2 points (6); skin thickening of the fingers (puffy fingers - score 2; sclerodactyly of the fingers - score 4), only the higher score is counted (7); skin thickening of both hands proximal to the metacarpophalangeal joints is scored with 9 points (8). A score  $\geq 9$  is necessary for a definite diagnosis of SSc [46, 47].

## 6.2. Raynaud's phenomenon in mixed connective tissue disease

MCTD combines symptoms of systemic lupus erythematosus (SLE), SSc, polymyositis (PM)/DM, arthritis, and the presence of a specific immunologic marker—anti-U1 RNP (an antibody against extractable nuclear antigen)—the latter being an obligatory classification criterion for the disease [48]. RP is met in 85% of patients with MCTD [8] and is the most common initial symptom [49]. Currently, the classification criteria for MCTD used in clinical practice are suggested by different author groups and not by professional organizations (criteria of Alarcon-Segovia, Kasukawa, Sharp, Kahn). RP is included in all of them because of its high frequency in MCTD [50]. Of note, the "SSc-like" capillaroscopic changes could be observed in a significantly lower proportion of MCTD patients in comparison with SSc. Maricq et al. have observed "SSc-like" pattern in 54% of cases in the examined group of 26 MCTD patients [36]. Bergman et al. detected "SSc-like" pattern in 50% (4/8) of the cases [51] and de Holanda Mafaldo Diógenes et al. in 65–71.5% [52]. Granier et al. observed a similar frequency of "scleroderma-like" capillaroscopic pattern—63.6% [53].

## 6.3. Raynaud's phenomenon in undifferentiated connective tissue disease

In UCTD patients, there are different symptoms of systemic rheumatic disease, but there is no full set of criteria of a well-defined rheumatic disorder. RP is a frequent symptom that may be observed in about 80% of the patients with UCTD. In evolution, a proportion of these patients (1/4–1/3) develop a distinct rheumatic disease, the most frequent being SSc, SLE, rheumatoid arthritis (RA), and Sjögren syndrome, but the majority of cases remain in a clinically

and laboratory stable condition in the scope of the term “UCTD.” In UCTD, the frequency of “scleroderma-like pattern” is lower as compared with SSc (13.8%, Nagy et al. [41]; 38%, Lambova et al.) [34, 54]. The presence of “scleroderma-like” capillaroscopic pattern in patients with UCTD is considered to be a reliable predictive factor for the development of SSc [41].

#### **6.4. Raynaud’s phenomenon in systemic lupus erythematosus**

The prevalence of RP in SLE is between 10 and 45% [8]. Although in a proportion of cases with SLE peripheral vessel is affected by vasculitis, RP usually tends to have a benign course without the development of digital ulcers or necrosis [9]. Microvascular capillaroscopic changes in SLE are less specific vs. those in scleroderma-spectrum disorders. However, several capillaroscopic features have been noted in SLE that are termed “SLE” type capillaroscopic pattern [51, 53, 55], which includes the presence of elongated [53, 56] and dilated capillary loops, tortuous and meandering capillaries [55], and prominent subpapillary plexus [53, 56]. “Scleroderma-like” capillaroscopic pattern is a rare finding in SLE with frequency varying between 2 and 15% [36, 41, 51, 56, 57]. An association between “scleroderma-like” capillaroscopic pattern and the presence of RP and anti-U1 RNP antibody has been observed that is suggested to be in the context of a possible subclinical overlap syndrome with SSc [57]. In an own study of 30 SLE patients, RP was found in 73% of cases, and “scleroderma-like” capillaroscopic pattern in 13.3% of the patients (4/30). Such changes were observed in patients with high immunological activity, two of whom were with active vasculitis of peripheral vessels and two with secondary RP. They did not exhibit signs of overlap with SSc or other CTD. Anti-RNP antibody was positive in a single case in a patient with symptoms of secondary RP without peripheral vessel vasculitis, while in the other three cases with “scleroderma-like” pattern, this immunological marker was negative [34, 54]. Thus, it could be concluded that “scleroderma-like” capillaroscopic pattern could be found in SLE patients with high immunological activity, both in cases with active vasculitis of peripheral vessels and only with symptoms of secondary RP but without evidence for overlap with SSc or other CTD.

#### **6.5. Raynaud’s phenomenon in dermatomyositis and polymyositis**

RP occurs in about 20% of DM/PM patients [8]. Digital gangrenes of the hands are usually not observed. When such changes are evident, the presence of neoplasm should be suspected. RP is characteristic for the antisynthetase syndrome, which is a subset of myositis characterized with positive anti-Jo-1 antibodies (against histidyl-tRNA synthetase), interstitial lung disease, nonerosive symmetric polyarthritis in small joints, and cracking and fissuring of the skin of the fingers (“mechanic’s hands”) [58]. In a part of the cases with DM, “scleroderma-like” capillaroscopic findings could be observed [35]. Although the capillaroscopic changes in DM and SSc are usually indistinguishable, it is suggested that bushy and branching capillaries could be found more frequently in DM [59]. The frequency of “SSc-like” pattern detected by Bergman et al. in 11 patients with DM was 63.6% [51].

#### **6.6. Raynaud’s phenomenon in rheumatoid arthritis**

The prevalence of RP in RA varies between 3 and 17% (2.7%, Carrol et al., North Australia [60]; 4.6%, Grassi et al., Italy [61]; and 17.2%, Saraux et al., France) [62]. In 31 RA patients, Redisch

et al. observed the following capillaroscopic changes: presence of elongated capillary loops, increased capillary tortuosity, and prominent subpapillary plexus. A "SSc-like" pattern was not detected in RA [55]. Nagy et al. also did not observe "SSc-like" pattern in a group of 14 patients with RA [41].

Of note, in an own study that included higher number of patients with RA (n = 62) with and without RP, a "SSc-like" pattern was observed in 14.5% (9/62; 2 males and 7 females). In one of the nine cases with such capillaroscopic changes, an overlap syndrome (RA overlap to SLE) with secondary RP and secondary vasculitis of peripheral vessels was evident. While in the rest eight out of nine patients, no overlap with other CTD was present. All RA patients with "SSc-like" capillaroscopic pattern (9/9) exhibited symptoms of secondary RP, and 2/9 a secondary vasculitis of peripheral vessels, respectively. Our results suggest that "SSc-like" capillaroscopic pattern could be observed in RA patients with secondary RP and with vasculitis of peripheral vessels although with low frequency. However, its presence is not mandatory in the context of overlap syndromes [34, 63].

### **6.7. Paraneoplastic Raynaud's phenomenon**

RP may be a paraneoplastic symptom. When RP is newly appeared with late onset after the age of 60, it may also be an indicator for an underlying malignancy. Ischemia of the fingers has been reported in patients with carcinomas of the breast, the stomach, and the esophagus as well as in patients with oncohematologic disease (multiple myeloma, thrombocythemia, etc.). In a part of the cases, paraneoplastic RP is caused by secretion of vasoactive substances by the tumor cells and the respective immune response of the body, while in others like multiple myeloma and thrombocytopenia, it is associated with increased blood viscosity [64, 65]. We have not observed differences between microvascular changes in paraneoplastic rheumatic conditions in comparison with the respective idiopathic rheumatic diseases [66].

### **6.8. Raynaud's phenomenon in fibromyalgia**

Fibromyalgia is an idiopathic, chronic, musculoskeletal, pain syndrome characterized with diffuse pain and presence of multiple tender points [67]. Primary fibromyalgia is an isolated disorder, while secondary fibromyalgia could be observed in different rheumatic diseases, e.g., RA, SLE, Sjögren syndrome, etc. [68]. RP is met in both primary and secondary fibromyalgia. The frequency of RP in fibromyalgia patients is about 17–30% [69, 70]. In an own study that included 26 patients with primary fibromyalgia, the most frequent capillaroscopic finding was the presence of dilated capillary loops analogous to primary RP. Capillaroscopic signs of microangiopathy were not detected [71].

## **7. Differential diagnosis of RP with other vascular acrosyndromes**

*Acrocyanosis* represents painless bluish discoloration in the distal body parts, most commonly in the hands and feet and less frequently in the face that are affected symmetrically. In acrocyanosis, the bluish skin discoloration is a persistent finding that is aggravated by cold exposure and frequently is associated with local hyperhidrosis and edema of the hands and feet. In the

absence of an accompanying cause, acrocyanosis is considered primary (idiopathic, essential) that is suggested to be a benign condition and typically does not require specific treatment. It does not evolve into CTD or other diseases and may spontaneously resolve. Secondary acrocyanosis is a manifestation of other major diseases. Both acrocyanosis and RP are influenced by cold exposure and emotional stress, but in acrocyanosis, there is relative persistence of skin color changes, symmetry, and absence of paroxysmal pallor. Of note, RP may occur concomitantly with acrocyanosis. In addition, the persistence of acrocyanosis is also relative, and it may also demonstrate improvement in the summer as well as in horizontal and elevated position of the hand vs. dependent position [72].

*Perniosis (chilblain)* is a localized cutaneous inflammatory reaction in response to acute or repetitive exposure to damp cold above the freezing point. The skin lesions are edematous plaques that may be purple or red and are often painful or pruritic. In severe cases, ulceration, superinfection, and scarring may occur. Fingers and toes are most commonly affected although other areas, e.g., nose, ears, buttocks, or thighs, could also be involved. Primary and secondary forms are recognized. Secondary perniosis could be associated with a variety of underlying pathological conditions such as hepatitis, autoimmune disease, and cryopathies [73].

*Erythromelalgia* is characterized with episodic, symmetric, and painful hyperthermia and erythema of hands and feet. Contrary to RP, erythromelalgia is provoked by exposure to heat or physical exercise. Primary and secondary forms are also recognized, primary being a rare hereditary disease that manifests in children and young people, while secondary is met in the context of myeloproliferative disorders, diabetes, and SLE and during drug treatment with calcium channel blockers (CCBs) [74].

## 8. Treatment

### 8.1. Primary RP

The mild forms of primary RP are controlled by non-pharmacological measures, e.g., patient education in avoiding exposure to cold, use of warm clothes and gloves, smoking cessation, using protective devices in working with vibration. Caffeine consumption, administration of vasoconstrictors such as beta-blockers, and use of interferons should be avoided when possible [9].

*Dihydropyridine-type CCBs* have been the treatment of choice for patients with both primary and secondary RP for many years. They have proven efficacy for reduction of the severity and frequency of ischemic attacks in primary RP and secondary RP in SSc. Diltiazem (benzothiazepine class CCBs) could also be used in RP. It is administered at a dose of 30–120 mg three times daily orally. Verapamil (diphenylalkylamine class of CCBs) does not possess therapeutic effect in RP patients [75–77]. Nifedipine is the best studied and the most often used drug from dihydropyridine class CCBs. It is used at a dose of 10–40 mg twice daily orally. Other dihydropyridines commonly used in patients with RP are felodipine (2.5–10 mg twice daily orally) and amlodipine (5–10 mg daily orally) [1, 9]. Dihydropyridine class CCBs are vasodilators with direct effect on vascular smooth muscles. They are indicated for the treatment of

arterial hypertension and stable angina, and some of them are also officially approved for vasospastic angina [78]. In RP patients, their use is off-label. Side effects of CCBs are common, e.g., flushing, hypotension, dizziness, headache, tachycardia, ankle edema, constipation, etc. Slow-release forms are better tolerated and preferred in clinical practice [1]. Pregnancy is a contraindication for administration of CCBs—a fact that deserves attention considering the high prevalence of primary RP in young women. This patient category requires specific instructions, and those women at childbearing age who plan conception or do not use effective contraception should not receive CCBs. Alternative, better-tolerated therapeutic options are often preferred in primary RP considering the milder clinical course and good prognosis of this condition as well as the side effects of CCBs.

*Pentoxifylline* inhibits phosphodiesterase and elevates cyclic adenosine monophosphate (cAMP) levels in polymorphonuclear leukocytes and other cells [79]. It exerts beneficial effects on microcirculation via improvement of blood fluidity, especially influencing erythrocyte flexibility [80]. Its maximal daily dose is 1200 mg (400 mg three times daily or 600 mg twice daily orally). It is not proven to be effective in severe forms of RP [1].

Therapeutic effect of *Ginkgo biloba* has been studied in patients with primary RP in double-blind, placebo-controlled trial. Significant reduction in the number of attacks has been observed in the group treated with high dose of *Ginkgo biloba* (360 mg daily) as compared with the placebo group (56 vs. 27%). It is suggested that *Ginkgo biloba* together with its vasodilator properties possesses also antiplatelet and radical scavenging effects [81].

## 8.2. Secondary RP in systemic sclerosis

EULAR recommends *dihydropyridine-type* CCBs as first-line therapy for RP in SSc [82]. A meta-analysis, including 8 randomized clinical trials (7 with nifedipine and 1 with nifedipine) with 109 SSc patients, indicates that dihydropyridine-type CCBs reduce the frequency and severity of ischemic attacks in SSc-related RP [77]. Apart from their effect to reduce the severity and frequency of vasospastic attacks, it has been demonstrated that CCBs lead to healing of digital ulcers [83]. In SSc with severe RP and/or those who do not respond satisfactorily to CCBs, *phosphodiesterase-5 enzyme inhibitors* are recommended (EULAR recommendation) [82]. NO is the main endothelium-derived vasodilator and an inhibitor of platelet activation and vascular smooth muscle proliferation. Its synthesis is regulated by the family of NO synthases, and its effect is mediated via cyclic guanosine monophosphate (cGMP). The intracellular concentration of cGMP is regulated by phosphodiesterases, which rapidly degrade cGMP in vivo [84]. A meta-analysis, including six randomized clinical trials (two with sildenafil, three with tadalafil, and one with vardenafil), demonstrated that phosphodiesterase-5 inhibitors have a significant effect on frequency and duration of RP attacks. Efficacy on healing of digital ulcers has been also reported. The therapeutic regimens used were as follows: sildenafil 50 mg twice daily or 200 mg once daily, tadalafil 20 mg daily or 20 mg on alternate days, and vardenafil 10 mg twice daily. The dosage regimens depend on half-lives of the different drugs that are 3–5 h for sildenafil and vardenafil (administered twice daily apart from modified-release sildenafil that is administered as a single dose) and about 18 h for tadalafil (administered once daily or on alternate days) [85]. Side effects during treatment with phosphodiesterase-5

inhibitors included different forms of vasomotor reactions, myalgias, allergic reaction, chest pain, dyspepsia, nasal stuffiness, and visual abnormalities. Considering long-term experience and good safety profile, EULAR experts recommend CCBs as first-line therapy for SSc-related RP and phosphodiesterase-5 inhibitors for SSc with severe RP and/or in cases with insufficient effect from the treatment with CCBs [82].

*Intravenous iloprost* possesses proven efficacy for reduction of the frequency and severity of SSc-related RP. Considering costs and feasibility, it is recommended after failure of oral therapies (CCBs and phosphodiesterase-5 inhibitors). Intravenous iloprost is also efficacious in the treatment of digital ulcers in SSc that is proved in randomized, placebo-controlled clinical trials [86, 87]. However, the need for hospitalization, the prolonged intravenous infusion (6 hours at the dose of 0.5–2 ng/kg/min), side effects, and high price are limiting factors for the administration of iloprost. Adverse effects include headache, nausea, vomiting, diarrhea, myalgia, arthralgia, chills, fever, arrhythmia, hypotension, chest pain (especially in patients with coronary heart disease), erythema, and pain at the infusion site. Thus, concomitant pathology should be assessed and hemodynamic parameters of the patients closely observed, e.g., blood pressure, heart rate, and pulse at the beginning and at every increase of the infusion rate. The risk for orthostatic hypotension should be also considered. Apart from its properties as a vasodilator, iloprost inhibits platelet aggregation, leukocyte chemotaxis, and adhesion to the endothelium. Iloprost also downregulates the expression of adhesion molecules on endothelial cells and phagocytes and enhances fibrinolytic activity [86–88].

In addition, in the most recent EULAR recommendation, *fluoxetine* (a serotonin-specific reuptake inhibitor and antidepressant) is suggested as an option in SSc-related RP despite the scarce published evidence [82]. In a small study that included 26 patients with primary RP and 27 with SSc-related RP, fluoxetine (20 mg daily) showed superior efficacy vs. nifedipine (40 mg daily). Observed side effects of fluoxetine were apathy, lethargy, and impaired concentration [89]. Despite the relatively low quality of published evidence, EULAR experts suggest fluoxetine as a useful alternative for treatment of SSc-related RP, especially in SSc patients who do not tolerate or fail to respond to vasodilators [82].

In SSc patients, in whom RP has complicated with digital ulcers, EULAR experts recommend *intravenous iloprost* and *phosphodiesterase-5 inhibitors* for treatment of digital ulcers and *bosentan* (*endothelin receptor antagonist*) for reduction of the number of new digital ulcers [82].

## 9. Prognosis

Being a first symptom in a number of CTD, the presence of RP requires regular follow-up that includes clinical, laboratory, immunological, and capillaroscopic assessment. The appearance of pathological capillaroscopic picture inherits a higher positive predictive value (47%) for the development of CTD vs. the predictive value of the positive ANA test (30%) [15]. Thus, nailfold capillaroscopy is the key investigation for monitoring RP patients. The interval of follow-up is 6 months, because a longer period of time is usually necessary for the development of morphological capillaroscopic changes, but this period may be shorter in cases with newly appeared alarming symptoms.

## Author details

Sevdalina Nikolova Lambova

Address all correspondence to: [sevdalina\\_n@abv.bg](mailto:sevdalina_n@abv.bg)

Department of Propaedeutics of Internal Diseases, Faculty of Medicine, Medical University, Plovdiv, Bulgaria

## References

- [1] Wigley FM. Raynaud's phenomenon. *The New England Journal of Medicine*. 2002;**347**(13): 1001-1008
- [2] Maricq HR, Weinrich MC. Diagnosis of Raynaud's phenomenon assisted by color charts. *The Journal of Rheumatology*. 1988;**15**:454-459
- [3] Maverakis E, Patel F, Kronenberg DG, Chung L, Fiorentino D, Allanore Y, et al. International consensus criteria for the diagnosis of Raynaud's phenomenon. *Journal of Autoimmunity*. 2014;**48-49**:60-65
- [4] Cortes S, Cutolo M. Capillaroscopic patterns in rheumatic diseases. *Acta Reumatológica Portuguesa*. 2007;**32**:29-36
- [5] Ho M, Belch JFF. Raynaud's phenomenon: State of the art 1998. *Scandinavian Journal of Rheumatology*. 1998;**27**:319-322
- [6] Wigley FM, Flavahan NA. Raynaud's phenomenon. *The New England Journal of Medicine*. 2016;**375**(6):556-565
- [7] Chikura B, Moore T, Manning J, Vail A, Herrick AL. Thumb involvement in Raynaud's phenomenon as an indicator of underlying connective tissue disease. *The Journal of Rheumatology*. 2010;**37**:783-786
- [8] Khan F. Vascular abnormalities in Raynaud's phenomenon. *Scottish Medical Journal*. 1999;**44**(1):4-6
- [9] Block JA, Sequeira W. Raynaud's phenomenon. *Seminars Lancet*. 2001;**357**:2042-2048
- [10] Herrick AL. The pathogenesis, diagnosis and treatment of Raynaud phenomenon. *Nature Reviews Rheumatology*. 2012;**8**(8):469-479
- [11] Müller-Ladner U. *Raynaud's Phenomenon and Peripheral Ischemic Syndromes*. 1st ed. Bremen: UNI-MED Verlag AG; 2008. pp. 18-30
- [12] Husein-Elahmed H et al. Severe Raynaud syndrome induced by adjuvant interferon alfa in metastatic melanoma. *Current Oncology*. 2010;**17**(4):122-123
- [13] Lapossy E, Gasser P, Hrycaj P, et al. Cold-induced vasospasm in patients with fibromyalgia and chronic low back pain in comparison to healthy subjects. *Clinical Rheumatology*. 1994;**13**(3):442-445

- [14] Steven AO. Raynaud's phenomenon. In: Sterling JB, editor. *Secrets of Rheumatology*. Moscow: Binom; 2001. pp. 614-619
- [15] Spencer-Green G. Outcomes in primary Raynaud phenomenon: A meta-analysis of the frequency, rates, and predictors of transition to secondary diseases. *Archives of Internal Medicine*. 1998;**158**(6):595-600
- [16] Coffman JD, Cohen RA. Role of alpha-adrenoceptor subtypes mediating sympathetic vasoconstriction in human digits. *European Journal of Clinical Investigation*. 1988;**18**: 309-313
- [17] Flavahan NA, Cooke JP, Shepherd JT, Vanhoutte PM. Human postjunctional alpha-1 and alpha-2 adrenoceptors: Differential distribution in arteries of the limbs. *The Journal of Pharmacology and Experimental Therapeutics*. 1987;**241**(2):361-365
- [18] Chotani MA, Flavahan S, Mitra S, et al. Silent alpha-2c-adrenergic receptors enable cold-induced vasoconstriction in cutaneous arteries. *American Journal of Physiology. Heart and Circulatory Physiology*. 2000;**278**(4):H1075-H1083
- [19] Jeyaraj SC, Chotani MA, Mitra S, Gregg HE, Flavahan NA, Morrison KJ. Cooling evokes redistribution of  $\alpha$ 2c-adrenoceptors from golgi to plasma membrane in transfected human embryonic kidney 293 cells. *Molecular Pharmacology*. 2001;**60**:1195-1200
- [20] Eid AH, Chotani MA, Mitra S, Miller TJ, Flavahan NA. Cyclic AMP acts through Rap1 and JNK signaling to increase expression of cutaneous smooth muscle alpha2C-adrenoceptors. *American Journal of Physiology-Heart and Circulatory Physiology*. 2008;**295**(1): H266-H272
- [21] Furspan PB, Chatterjee S, Freedman RR. Increased tyrosine phosphorylation mediates the cooling-induced contraction and increased vascular reactivity of Raynaud's disease. *Arthritis and Rheumatism*. 2004;**1578-1585**(2004):50
- [22] Furspan PB, Chatterjee S, Mayes MD, Freedman RR. Cooling-induced contraction and protein tyrosine kinase activity of isolated arterioles in secondary Raynaud's phenomenon. *Rheumatology (Oxford)*. 2005;**44**:488-494
- [23] Müller-Ladner U, Lambova S. Editorial: Vascular damage in systemic sclerosis. *Current Rheumatology Reviews*. 2013;**9**(4):233-236
- [24] Rajagopalan S, Pfenninger D, Kehrer C, Chakrabarti A, Somers E, Pavlic R, et al. Increased asymmetric dimethylarginine and endothelin 1 levels in secondary Raynaud's phenomenon: Implications for vascular dysfunction and progression of disease. *Arthritis Rheum*. 2003;**48**(7):1992-2000
- [25] Vancheeswaran R, Azam A, Black C, Dashwood MR. Localization of endothelin-1 and its binding sites in scleroderma skin. *The Journal of Rheumatology*. 1994;**21**:1268-1276
- [26] Jing J, Dou TT, Yang JQ, Chen XB, Cao HL, Min M, et al. Role of endothelin-1 in the skin fibrosis of systemic sclerosis. *European Cytokine Network*. 2015;**26**(1):10-14
- [27] Zamora MR, O'Brien RF, Rutherford RB, Weil JV. Serum endothelin-1 concentrations and cold provocation in primary Raynaud's phenomenon. *Lancet*. 1990;**336**:1144-1147

- [28] Bunker CB, Terenghi G, Springall DR, Polak JM, Dowd PM. Deficiency of calcitonin gene-related peptide in Raynaud's phenomenon. *Lancet*. 1990;**336**:1530-1533
- [29] Garner R, Kumari R, Lanyon P, Doherty M, Zhang W. Prevalence, risk factors and associations of primary Raynaud's phenomenon: systematic review and meta-analysis of observational studies. *BMJ Open*. 2015;**5**(3):e006389
- [30] Planchon B, Pistorius M-A, Beurrier P, de Faucal P. Primary Raynaud's phenomenon: age of onset and pathogenesis in a prospective study of 424 patients. *Angiology*. 1994;**45**:677-686
- [31] Le Roy EC, Medsger TA Jr. Raynaud's phenomenon: a proposal for classification. *Clinical and Experimental Rheumatology*. 1992;**10**(5):485-488
- [32] Anderson ME et al. Computerized nailfold videocapillaroscopy – A new tool for assessment of Raynaud's phenomenon. *The Journal of Rheumatology*. 2005;**32**:841-848
- [33] Bukhari M et al. Quantitation of microcirculatory abnormalities in patients with primary Raynaud's phenomenon and systemic sclerosis by videocapillaroscopy. *Rheumatology*. 2000;**39**(5):506-512
- [34] Lambova S. The role of capillaroscopy in rheumatology [dissertation]. Giessen, Germany: Justus Liebig University; 2011
- [35] Maricq HR, Le Roy EC. Patterns of finger capillary abnormalities in connective tissue disease by "wide-field" microscopy. *Arthritis & Rheumatism*. 1973;**16**(5):619-628
- [36] Maricq HR et al. Diagnostic potential of in vivo capillary microscopy in scleroderma and related disorders. *Arthritis and Rheumatism*. 1980;**23**(2):183-189
- [37] Maricq HR et al. Microvascular abnormalities as possible predictors of disease subsets in Raynaud phenomenon and early connective tissue disease. *Clinical and Experimental Rheumatology*. 1983;**1**(3):195-205
- [38] Cutolo M, Sulli A, Pizzorni C, Accardo S. Nailfold videocapillaroscopy assessment of microvascular damage in systemic sclerosis. *The Journal of Rheumatology*. 2000;**27**:155-160
- [39] Lambova S, Hermann W, Müller-Ladner U. Capillaroscopic pattern at the toes of systemic sclerosis patients: does it "tell" more than those of fingers? *Journal of Clinical Rheumatology*. 2011;**17**(6):311-314
- [40] Lambova S, Müller-Ladner U. Capillaroscopic findings in systemic sclerosis--are they associated with disease duration and presence of digital ulcers? *Discovery Medicine*. 2011;**12**(66):413-418
- [41] Nagy Z, Czirjac L. Nailfold digital capillaroscopy in 447 patients with connective tissue disease and Raynaud` disease. *Journal of the European Academy of Dermatology and Venereology*. 2004;**18**:62-68
- [42] Subcommittee for scleroderma criteria of the American Rheumatism Association Diagnostic and Therapeutic Criteria Committee. Preliminary criteria for the classification of systemic sclerosis (scleroderma). *Arthritis and Rheumatism*. 1980;**23**(5):581-590

- [43] Hudson M et al. Improving the sensitivity of the American College of Rheumatology classification criteria for systemic sclerosis. *Clinical and Experimental Rheumatology*. 2007;**25**(5):754-757
- [44] Lonzeiti LS et al. Updating the American College of Rheumatology preliminary classification criteria for systemic sclerosis: Addition of severe nailfold capillaroscopy abnormalities markedly increases the sensitivity for limited scleroderma. *Arthritis and Rheumatism*. 2001;**44**(3):735-736
- [45] Le Roy EC, Medsger TA Jr. Criteria for the classification of early systemic sclerosis. *The Journal of Rheumatology*. 2001;**28**:573-576
- [46] van den Hoogen F, Khanna D, Fransen J, et al. 2013 classification criteria for systemic sclerosis: An American college of rheumatology/European league against rheumatism collaborative initiative. *Annals of the Rheumatic Diseases*. 2013;**72**(11):1747-1755
- [47] van den Hoogen F, Khanna D, Fransen J, et al. 2013 classification criteria for systemic sclerosis: An American college of rheumatology/European league against rheumatism collaborative initiative. *Arthritis and Rheumatism*. 2013;**65**(11):2737-2747
- [48] Sharp GC, Irvin WS, Tan EM, Gould RG, Holman HR. Mixed connective tissue disease--an apparently distinct rheumatic disease syndrome associated with a specific antibody to an extractable nuclear antigen (ENA). *The American Journal of Medicine*. 1972;**52**(2):148-159
- [49] Bennett RM, O'Connell DJ. The arthritis of mixed connective tissue disease. *Annals of the Rheumatic Diseases*. 1978;**37**(5):397-403
- [50] Smolen JS, Steiner G. Mixed connective tissue disease: To be or not to be? *Arthritis and Rheumatism*. 1998;**41**(5):768-777
- [51] Bergman R, Sharony L, Schapira D, et al. The handheld dermatoscope as a nail-fold capillaroscopic instrument. *Archives of Dermatology*. 2003;**139**:1027-1030
- [52] de Holanda Mafaldo Diógenes A, Bonfá E, Fuller R, Correia Caleiro MT. Capillaroscopy is a dynamic process in mixed connective tissue disease. *Lupus*. 2007;**16**(4):254-258
- [53] Granier F, Priollet P, Housset E. Nailfold capillary microscopy in mixed connective tissue disease. Comparison with systemic sclerosis and systemic lupus erythematosus. *Arthritis and Rheumatism*. 1986;**29**(2):189-195
- [54] Lambova S, Müller-Ladner U. Capillaroscopic pattern in systemic lupus erythematosus and undifferentiated connective tissue disease—What we still have to learn? *Rheumatology International*. 2013;**33**(3):689-695
- [55] Redisch W. Capillaroscopic observations in rheumatic diseases. *Annals of the Rheumatic Diseases*. 1970;**29**:244-253
- [56] Kabasakal Y, Elvins DM, Ring EF, McHugh NJ. Quantitative nailfold capillaroscopy findings in a population with connective tissue disease and in normal healthy controls. *Annals of the Rheumatic Diseases*. 1996;**55**:507-512

- [57] Furtado RNV, Pucinell MLC, Cristo VV, Andrade LEC, Sato EI. Scleroderma-like nailfold capillaroscopic abnormalities are associated with anti-U1-RNP antibodies and Raynaud's phenomenon in SLE patients. *Lupus*. 2002;**11**(1):35-41
- [58] Seibold JR, Steen VD. Systemic sclerosis. In: Klippel JH, Dieppe PA, editors. *Rheumatology*. London: Mosby; 1994. pp. 6.8-6.11
- [59] Kenik JG, Maricq HR, Bole GG. Blind evaluation of the diagnostic specificity of nailfold capillary microscopy in the connective tissue diseases. *Arthritis and Rheumatism*. 1981;**24**(7):885-891
- [60] Carrol GJ, Withers K, Bayliss CE. The prevalence of Raynaud's syndrome in rheumatoid arthritis. *Annals of the Rheumatic Diseases*. 1981;**40**:567-570
- [61] Grassi W, Blasetti P, Core P, Cervini C. Raynaud's phenomenon in rheumatoid arthritis. *British Journal of Rheumatology*. 1994;**33**:139-141
- [62] Saraux A, Allain J, Guedes C, Baron D, Youinou P, Le Goff P. Raynaud's phenomenon in rheumatoid arthritis. *British Journal of Rheumatology*. 1996;**35**(8):752-754
- [63] Lambova SN, Müller-Ladner U. Capillaroscopic pattern in inflammatory arthritis. *Microvascular Research*. 2012;**83**(3):318-322
- [64] Ling SM, Wigley FM. Raynaud's phenomenon in older adults. Diagnostic considerations and management. *Drugs & Aging*. 1999;**15**(3):183-195
- [65] Paw P, Dharan SM, Sackier JM. Digital ischemia and occult malignancy. *International Journal of Colorectal Disease*. 1996;**11**:196-197
- [66] Lambova S, Müller-Ladner U. Capillaroscopic pattern in paraneoplastic Raynaud's phenomenon. *Rheumatology International*. 2013;**33**(6):1597-1599
- [67] Di Franco M, Iannuccelli C, Valesini G. Neuroendocrine immunology of fibromyalgia. *Annals of the New York Academy of Sciences*. 2010;**1193**:84-90
- [68] Wolfe F, Cathey MA, Kleinheksel SM. Fibrositis (Fibromyalgia) in rheumatoid arthritis. *The Journal of Rheumatology*. 1984;**11**(6):814-818
- [69] Wolfe F, Smythe HA, Yunus MB, et al. The American College of rheumatology 1990 criteria for the classification of fibromyalgia. Report of the Multicenter Criteria Committee. *Arthritis and Rheumatism*. 1990;**33**(2):160-172
- [70] Dinerman H, Goldenberg DL, Felson DT. A prospective evaluation of 118 patients with the fibromyalgia syndrome: Prevalence of Raynaud's phenomenon, sicca symptoms, ANA, low complement, and Ig deposition at the dermal-epidermal junction. *The Journal of Rheumatology*. 1986;**13**(2):368-373
- [71] Lambova S, Müller-Ladner U. Capillaroscopic findings in primary fibromyalgia. *Current Rheumatology Reviews*. 2018;**14**(1):36-41
- [72] Kurklinsky AK, Miller VM, Rooke TW. Acrocyanosis: The flying Dutchman. *Vascular Medicine*. 2011;**16**(4):288-301

- [73] Baker JS, Miranpuri S. Perniosis a case report with literature review. *Journal of the American Podiatric Medical Association*. 2016;**106**(2):138-140
- [74] Ahrazoglu M, Moinzadeh P, Hunzelmann N. Differential diagnoses of Raynaud's phenomenon. *Deutsche Medizinische Wochenschrift*. 2014;**139**(20):1064-1069
- [75] Rirash F, Tingey PC, Harding SE, Maxwell LJ, Tanjong Ghogomu E, Wells GA, et al. Calcium channel blockers for primary and secondary Raynaud's phenomenon. *Cochrane Database of Systematic Reviews*. 2017;**12**:CD000467. DOI: 10.1002/14651858.CD000467.pub2
- [76] Thompson AE, Pope JE. Calcium channel blockers for primary Raynaud's phenomenon: A meta-analysis. *Rheumatology (Oxford, England)*. 2005;**44**(2):145-150
- [77] Thompson AE, Shea B, Welch V, Fenlon D, Pope JE. Calcium-channel blockers for Raynaud's phenomenon in systemic sclerosis. *Arthritis and Rheumatism*. 2001;**44**(8):1841-1847
- [78] Godfraind T. Discovery and development of calcium channel blockers. *Frontiers in Pharmacology*. 2017;**8**:286. DOI: 10.3389/fphar.2017.00286. eCollection 2017
- [79] Maderazo EG, Breaux S, Woronick CL, Krause PJ. Efficacy, toxicity, and pharmacokinetics of pentoxifylline and its analogs in experimental *Staphylococcus aureus* infections. *Antimicrobial Agents and Chemotherapy*. 1990;**34**(6):1100-1106
- [80] Neirotti M, Longo F, Molaschi M, Macchione C, Pernigotti L. Functional vascular disorders: Treatment with pentoxifylline. *Angiology*. 1987;**38**(8):575-580
- [81] Muir AH, Robb R, McLaren M, Daly F, Belch JJ. The use of *Ginkgo biloba* in Raynaud's disease: a double-blind placebo-controlled trial. *Vascular Medicine*. 2002;**7**(4):265-267
- [82] Kowal-Bielecka O, Fransen J, Avouac J, Becker M, Kulak A, Allanore Y, Distler O, et al. Update of EULAR recommendations for the treatment of systemic sclerosis. *Annals of the Rheumatic Diseases*. 2017;**76**(8):1327-1339
- [83] Rademaker M, Cooke ED, Almond NE, et al. Comparison of intravenous infusions of iloprost and oral nifedipine in treatment of Raynaud's phenomenon in patients with systemic sclerosis: A double blind randomised study. *BMJ*. 1989;**298**:561-564
- [84] Kumana CR, Cheung GTY, Lau CS. Severe digital ischaemia treated with phosphodiesterase inhibitors. *Annals of the Rheumatic Diseases*. 2004;**63**:1522-1524
- [85] Roustit M, Blaise S, Allanore Y, et al. Phosphodiesterase-5 inhibitors for the treatment of secondary Raynaud's phenomenon: Systematic review and meta-analysis of randomised trials. *Annals of the Rheumatic Diseases*. 2013;**72**:1696-1699
- [86] Wigley FM, Seibold JR, Wise RA, et al. Intravenous iloprost treatment of Raynaud's phenomenon and ischemic ulcers secondary to systemic sclerosis. *The Journal of Rheumatology*. 1992;**19**:1407-1414

- [87] Wigley FM, Wise RA, Seibold JR, et al. Intravenous iloprost infusion in patients with Raynaud phenomenon secondary to systemic sclerosis. A multicenter, placebo-controlled, double-blind study. *Annals of Internal Medicine*. 1994;**120**:199-206
- [88] Bettoni L, Geri A, Airò P, et al. Clinical systemic sclerosis therapy with iloprost: A prospective observational study of 30 patients treated for a median of 3 years. *Clinical Rheumatology*. 2002;**21**:244-250
- [89] Coleiro B, Marshall SE, Denton CP, et al. Treatment of Raynaud's phenomenon with the selective serotonin reuptake inhibitor fluoxetine. *Rheumatology (Oxford)*. 2001;**40**: 1038-1043

IntechOpen

