

This article is licensed under the Creative Commons Attribution-NonCommercial 4.0 International License (CC BY-NC) (<http://www.karger.com/Services/OpenAccessLicense>). Usage and distribution for commercial purposes requires written permission.

Single Case

Acute Appendicitis Caused by Previous Endoscopic Submucosal Dissection for an Adenoma Adjacent to the Appendiceal Orifice

Ryo Kato^a Keita Harada^b Kei Harada^a Daisuke Takei^b
Yuusaku Sugihara^a Shiho Takashima^a Toshihiro Inokuchi^a
Masahiro Takahara^a Sakiko Hiraoka^a Yasushi Omura^c Wakako Oda^d
Hiroyuki Okada^a

^aDepartment of Gastroenterology and Hepatology, Okayama University Graduate School of Medicine, Dentistry and Pharmaceutical Sciences, Okayama, Japan; ^bDivision of Endoscopy, Okayama University Hospital, Okayama, Japan; ^cDepartment of Surgery, Okayama City Hospital, Okayama, Japan; ^dDepartment of Pathology and Clinical Examination, Okayama City Hospital, Okayama, Japan

Keywords

Tumors adjacent to appendiceal orifice · Acute appendicitis · Endoscopic submucosal dissection · Complications · Late complications

Abstract

Endoscopic submucosal dissection (ESD) is a groundbreaking treatment for tumors adjacent to the appendiceal orifice that are difficult to remove by conventional endoscopic mucosal resection, and successful cases are increasingly reported. However, little is known about the subsequent complications, especially long-term complications. A female in her early 70s with a 15-mm cecal tumor adjacent to the appendiceal orifice – discovered incidentally during a screening colonoscopy – underwent hybrid ESD of the lesion. We completely resected the tumor, and she was discharged 5 days later with a pathological diagnosis of high-grade tubular adenoma. Ten months postoperatively, she experienced sudden-onset right lower quadrant pain and was diagnosed with acute appendicitis at another hospital. Due to suspi-

cion that her condition was the result of residual tumor, her surgeon performed an emergency laparoscopic cecectomy. The pathological examination of the resected specimen showed thick scarring adjacent to the appendiceal orifice and no residual tumor. The previous ESD was identified as the cause of the scar, and the scar was the only finding to account for the patient's appendicitis. This case is significant because the patient required additional surgery due to a complication of ESD. Further, it indicates that acute appendicitis may be a late complication of submucosal dissection near the appendiceal orifice. As ESD becomes more widely used, it is likely that more cecal tumors will be treated endoscopically. It is important to be aware of the late complications of ESD for these tumors.

© 2017 The Author(s)
Published by S. Karger AG, Basel

Introduction

Appendicitis is caused by bacterial infection and proliferation in the closed environment resulting from obstruction of the appendiceal orifice. The most frequent cause of obstruction is fecalith [1], followed by lymphoid hyperplasia, neoplasms, foreign bodies, and parasitic infection [2, 3]. Several investigators have reported that colonoscopy may cause appendicitis by increasing intraluminal pressure [4]. Others have reported cases of endoscopic resection (ER) for tumors adjacent to the appendiceal orifice complicated by appendicitis. Appendicitis occurred soon after the ER in most of these cases and was considered to be related to a mucosal or submucosal injection or postpolypectomy coagulation syndrome. Reports of appendicitis occurring as a late complication of ER are very scarce to date.

Endoscopic submucosal dissection (ESD) was developed over the last decade and has become a general treatment option for colorectal mucosal lesions. As ESD has become more widely used, the number of reported ESD-related complications has grown, providing more information about the type and frequency of such complications. Well-described early complications include perforation, which occurs in 2.3–8.2% of ESD cases either inter- or postoperatively [5]. Postoperative bleeding is another well-known complication of ESD. By comparison, little is known about the late complications of colorectal ESD that occur several months after the procedure.

Here, we present a case of appendicitis presenting over 10 months after a curative ESD that appears to have been caused by obstruction due to ESD-related scarring. The literature regarding complications of colorectal ESD is reviewed and discussed.

Case Report

A female in her early 70s was referred to our hospital for endoscopic treatment of a 15-mm laterally spreading tumor adjacent to the appendiceal orifice, which was detected incidentally during a screening colonoscopy. An ER of the lesion had been attempted at another hospital without success and only biopsy had been performed after that. Her comorbidities included hypertension, dyslipidemia, and osteoporosis. Her medical history was negative for previous abdominal surgery, allergies, smoking, and alcohol consumption.

Magnifying endoscopy with narrow-band imaging and chromoendoscopy suggested the tumor was a simple adenoma. After obtaining written informed consent, we performed ER of the tumor. We began injected glycerol into the submucosal layer and incised the mucosa bordering the appendix side of the tumor using a DualKnife® (Olympus Corp., Tokyo, Japan). Subsequently, the submucosal layer was carefully dissected using the same device. However,

due to the scarring and fibrosis resulting from the previous attempt at resection, the submucosal layer did not lift adequately, and the submucosal dissection was extremely difficult. Consequently, an intraoperative micro perforation occurred but was tightly closed by clips. When the tumor was almost resected by ESD, we completely removed it using a snare. The size of the lesion was 15 × 15 mm (Fig. 1). After the ESD, there was neither postoperative bleeding nor inflammatory reaction suggesting peritonitis. The patient was discharged 5 days after ESD as scheduled. Pathological examination revealed that the tumor was a high-grade tubular adenoma, and we diagnosed a curative resection of the lesion.

The patient initially did well after she was discharged. However, 10 months later she experienced sudden severe abdominal pain and a low-grade fever before a meal. She visited her family physician immediately. Physical examination disclosed localized rebound tenderness at McBurney's point at that time. The laboratory analysis revealed an inflammatory reaction with a leukocyte count of 14,700/μL (79.1% neutrophils) and a C-reactive protein level of 4.5 mg/dL. Therefore, she was suspected of having acute appendicitis requiring emergency surgery. She was transferred to a general hospital near the clinic.

Abdominal computed tomography showed appendiceal wall thickening and swelling, an intraluminal fecal calculus, and fluffing of the surrounding fat tissue. The patient was diagnosed with acute appendicitis and underwent emergency surgery. Because the surgeon suspected that her appendicitis was associated with residual tumor, the patient underwent a laparoscopic cecectomy. Intraoperatively, the appendix was firmly adherent to the terminal ileum and retroperitoneum, and the root of the appendix was intussuscepted into the cecal lumen.

Macroscopic examination of the resected specimen revealed a perforation in the central portion of the resected appendix and a thick scar obstructing the appendiceal orifice that did not allow the passage of a probe (Fig. 2). Microscopic examination revealed no residual tumor and identified a broad band of fibrotic tissue adjacent to the appendiceal orifice consistent with a scar (Fig. 3). The lesion was pathologically diagnosed as gangrenous appendicitis. The scar was attributed to the previous ESD and was the only cause of appendicitis identified.

The patient was discharged 4 days after surgery. Two months postoperatively, she underwent a 1-year ESD follow-up colonoscopy. This examination showed a postoperative scar, and there were no other findings.

Discussion

We experienced a case of appendicitis as a late complication of ESD for a tumor adjacent to the appendiceal orifice. Tumors close to the appendiceal orifice have historically been considered difficult to remove by endoscopy because anatomical features of the appendix, including the easily-perforated thin muscle layer and complex orifice structure, made snaring difficult, especially when attempting an en bloc resection. The development of the ESD method made the endoscopic treatment of these tumors dramatically safer and more reliable, and successful reports have been increasing [6, 7]. We have successfully performed ESD treatment in several cases like the one described here.

In the present case, appendicitis occurred over 10 months after the ESD. If this had occurred in the early post-ER period (within 24 h), the condition could easily have been identified as a complication of the ER [8, 9]. However, as appendicitis occurred long after the ER, the cause could not be definitively determined. Because residual tumor could not be ruled

out, the patient underwent cecectomy, resulting in overtreatment. This case is significant in that the patient required additional surgery despite curative resection of her tumor. Furthermore, our case also suggests there may be other cases of appendicitis occurring as a late complication of ER that have not been identified. Thorough follow-up may be difficult because patients with appendicitis are usually treated at the nearest hospital, and this is often not the hospital where the ESD was performed. Fortunately, we were able to follow up this patient due to the collaboration of 2 hospitals.

Although the perforation that occurred during ESD may have contributed to the late complication, it seems unlikely that the leakage directly caused appendiceal inflammation 10 months later. However, we cannot know conclusively that the perforation was unrelated to the occurrence of appendicitis, and this lack of certainty is a limitation.

This is the first case report of appendicitis that evidently occurred as a late complication of ER. We propose that acute appendicitis is an important late complication of successful ER of tumors adjacent to the appendiceal orifice. As the ESD method is becoming more widely used, the number of ERs performed for tumors close to the appendiceal orifice is likely to increase. Hereafter, we believe that patients should be informed about the risk of post-ER appendicitis during the process of obtaining their consent for ER of a tumor located in proximity to the appendiceal orifice.

Acknowledgment

The authors would like to thank Y. Furubayashi, MD, Okayama City Hospital, for collecting data.

Statement of Ethics

The authors have no ethical conflict to disclose.

Disclosure Statement

The authors declare no conflict of interest.

References

- 1 Raahave D, Christensen E, Moeller H, Kirkeby LT, Loud FB, Knudsen LL: Origin of acute appendicitis: fecal retention in colonic reservoirs: a case control study. *Surg Infect (Larchmt)* 2007;8:55–62.
- 2 Lai CW, Yue CT, Chen JH: Mucinous cystadenocarcinoma of the appendix mimics acute appendicitis. *Clin Gastroenterol Hepatol* 2013;11:e11.
- 3 Schwab D, Baum U, Hahn EG: Colonoscopic treatment of obstructive appendicitis caused by dislocation of a biliary stent. *Endoscopy* 2005;37:606.
- 4 Horimatsu T, Fu KI, Sano Y, et al: Acute appendicitis as a rare complication after endoscopic mucosal resection. *Dig Dis Sci* 2007;52:1741–1744.
- 5 Hotta K, Yamaguchi Y, Saito Y, Takao T, Ono H: Current opinions for endoscopic submucosal dissection for colorectal tumors from our experiences: indications, technical aspects and complications. *Dig Endosc* 2012;24(suppl 1):110–116.
- 6 Jacob H, Toyonaga T, Ohara Y, et al: Endoscopic submucosal dissection of cecal lesions in proximity to the appendiceal orifice. *Endoscopy* 2016;48: 829–836.

- 7 Iwai T, Hotta K, Imai K, et al: Early cecal cancer adjacent to the appendiceal orifice successfully treated by endoscopic submucosal dissection. *Gastrointest Endosc* 2016;83:260–261.
- 8 Kuriyama M: Acute appendicitis as a rare complication after colonoscopy. *Clin J Gastroenterol* 2014;7:32–35.
- 9 Nemoto Y, Tokuhisa J, Shimada N, Gomi T, Maetani I: Acute appendicitis following endoscopic mucosal resection of cecal adenoma. *World J Gastroenterol* 2015;21:8462–8466.

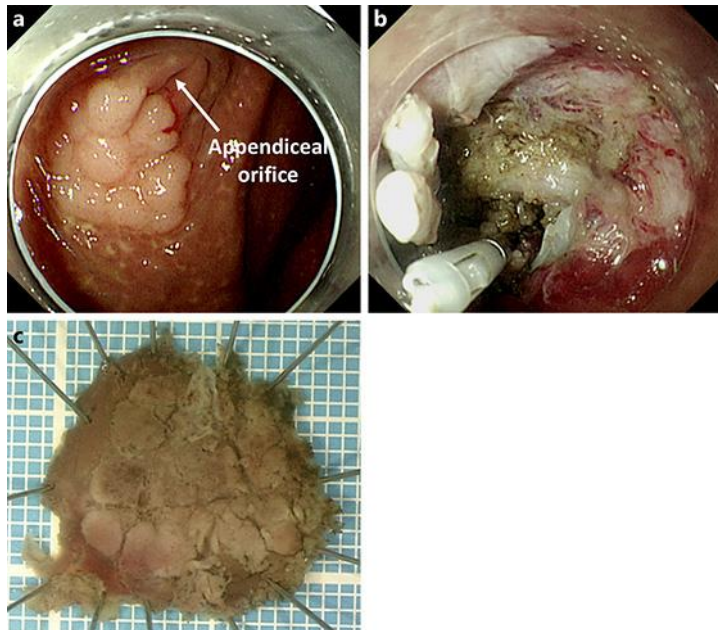


Fig. 1. Endoscopic submucosal dissection (ESD): intraoperative findings. **a** The treated tumor was adjacent to the appendiceal orifice. **b** The lesion just after ESD. **c** The size of the tumor was 15 × 15 mm.

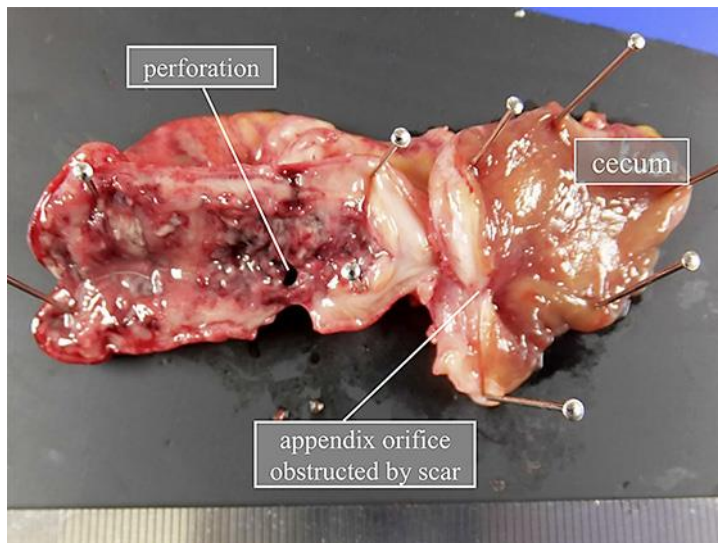


Fig. 2. Macroscopic findings of the resected specimen. The cecectomy specimen shows a thick scar obstructing the appendiceal orifice. The orifice did not admit a probe.

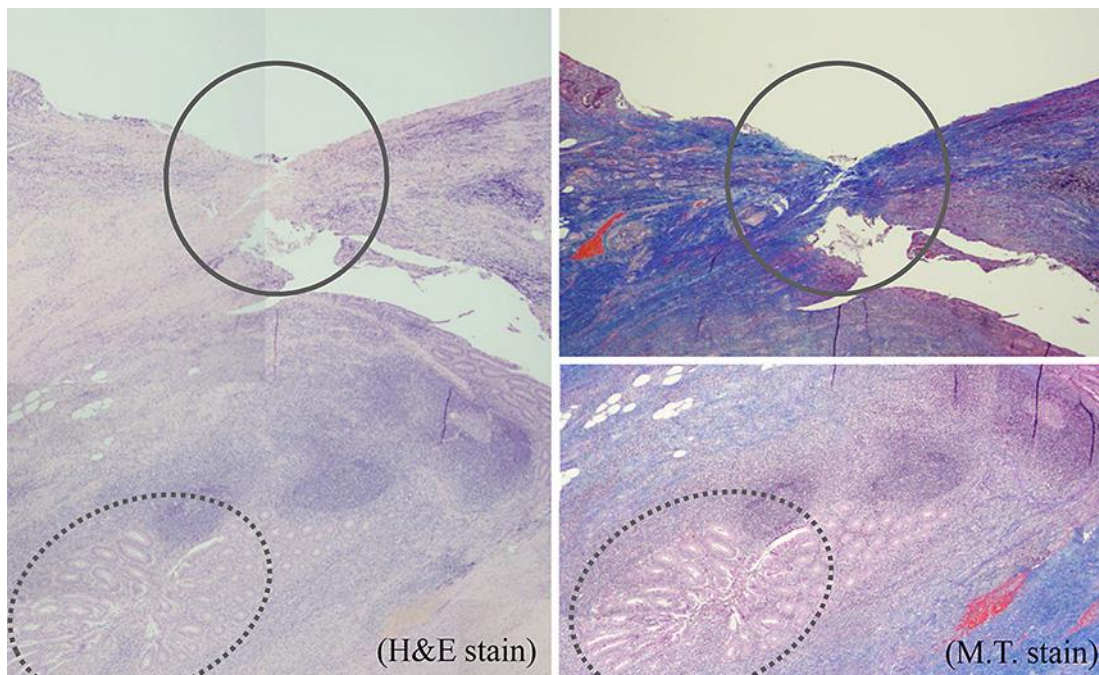


Fig. 3. Microscopic examination of the resected specimen. Sections near the appendiceal orifice (indicated by the solid circles) show an adjacent band of fibrotic tissue consistent with a thick scar. Fibrosis is markedly apparent with Masson trichrome staining. The lumen of the appendix is indicated by the dotted circles. H&E, hematoxylin and eosin stain; M.T., Masson trichrome stain.